



PATIENT

Gemma Guerrini

SPECIES

Canine

BREED

Chihuahua Mix

SEX

Female Spayed

AGE

9 years

WEIGHT

14.3lbs

PRESENTING CLINICAL SIGNS

History: "Trouble breathing" per owner; coughing at home. On exam, difficult to auscultate - no murmurs noted.; respirations appeared normal. Low CRT. Hypertensive (BP 170-180 mmHg). Radiographs: atrial bulge. *Sedated with torb/alfaxan.

ECHOCARDIOGRAM FINDINGS

2D, m-mode, color flow and Doppler imaging is available.

Left ventricle: The LV diameter is normal with adequate myocardial function. LV wall thicknesses are normal.

Left atrium: The left atrium is minimally dilated.

Mitral valve: The mitral valve is mildly thickened with no prolapse into the left atrial lumen. Trace/mild eccentric mitral regurgitation.

Aortic valve/aorta: The aortic valve is normal in morphology and mobility. Normal aortic outflow velocity; laminar flow. No aortic insufficiency.

Right ventricle: Normal right ventricular diameter and morphology indicating no overt evidence of pulmonary arterial hypertension.

Right atrium: Normal RA dimension.

Tricuspid valve: The tricuspid valve appears mildly thickened with trace tricuspid regurgitation.

Pulmonic valve/pulmonary artery: The pulmonic valve is normal in morphology and mobility. Trace pulmonic insufficiency. Normal RVOT velocity; laminar flow.

Pericardium/other: No pericardial or pleural effusion noted. No obvious cardiac masses.

Heart rhythm: ECG reveals a sinus rhythm with an average HR of 100bpm.

INTERPRETED BY

Maggie Machen
Lamy, DVM
DACVIM (Cardiology)

2-Dimensional Measurements

Ao diam (cm)	1.3
LA diam (cm)	2.0
LA:Ao (Swe)	1.5
IVS thickness (cm)	0.7
LVID diastole (cm)	2.4
PW thickness (cm)	0.7
LVID systole (cm)	1.1
FS (%)	53

Doppler Measurements

PV Vmax (m/s)	0.82
AoV Vmax (m/s)	1.6
MR Vmax (m/s)	NM
TR Vmax (m/s)	NM
TR PG (mmHg)	NA

IMAGING

PERFORMED BY

Pamela Harrigan,
RDCS

HOSPITAL NAME

Norfolk County
Veterinary Service

REFERRING VET

Dr. Richards

INTERPRETATION OF THE FINDINGS

The cause of the murmur is chronic degenerative valve disease causing trace leaks in the mitral and tricuspid valves. No significant chamber enlargement is noted, and the disease is well compensated for. No additional issues are identified. Assessment of progression in the future will help predict long term prognosis, which is highly variable at this stage (B1).

Given these findings, the cough is unlikely to be cardiac in origin and primary respiratory causes should be considered. Consider further respiratory work up/treatment (hydrocodone, taper course of steroids, Enrofloxacin, TTW/BAL, etc.).

INVOICE

22647

DATE

2/17/22



PATIENT

Gemma Guerrini

SPECIES

Canine

BREED

Chihuahua Mix

SEX

Female Spayed

AGE

9 years

WEIGHT

14.3lbs

INTERPRETED BY

Maggie Machen
 Lamy, DVM
 DACVIM (Cardiology)

IMAGING PERFORMED BY

Pamela Harrigan,
 RDCS

HOSPITAL NAME

Norfolk County
 Veterinary Service

REFERRING VET

Dr. Richards

INVOICE

22647

DATE

2/17/22

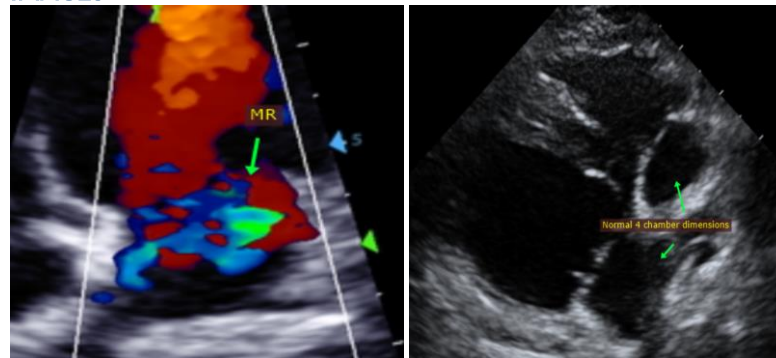
RECOMMENDATIONS

- In a dog without significant left atrial enlargement, no cardiac medications are clearly indicated.
- Omega fatty acid supplementation and mild salt restriction may be of some long-term benefit.
- Anesthetic risk is considered mild if needed. Cardiac protective drug choices (opioid/benzodiazepine premedication, propofol or alfaxalone induction, isoflurane gas) are recommended. Pre-oxygenate for 5-10 minutes prior to induction. Monitor for arrhythmias, hypotension, and hypoxia both intra and post-operatively and intervene as necessary. Mild IV fluid restriction is recommended to avoid fluid overload. Avoid heart rate stimulating drugs such as atropine unless clinically indicated.
- Monitor for development of a cough, labored breathing, exercise intolerance or collapse episodes.

PLAN

- Recommend conservative monitoring with a recheck echocardiogram in 6 months, sooner if any development of clinical signs.

IMAGES



The information and recommendations provided are based on the images presented by the referring veterinarian. No evaluation can be communicated regarding pathology that was not visible in the image/video clips provided.

Thank you for this referral. This report was generated using transcription software, and minor dictation errors may be present. If the clinical or image interpretation does not parallel your findings or if I can be of any further assistance, please contact me.

Maggie Machen Lamy, DVM
 Diplomate of the American College of Veterinary Internal Medicine (Cardiology)
 info@sonopath.com